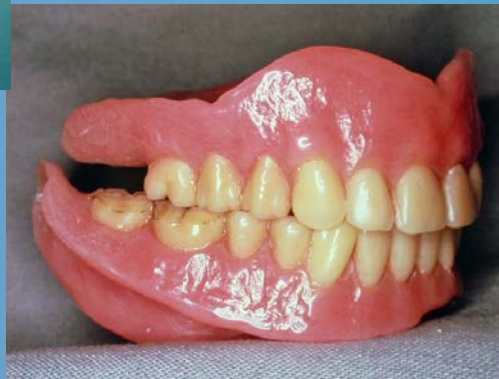
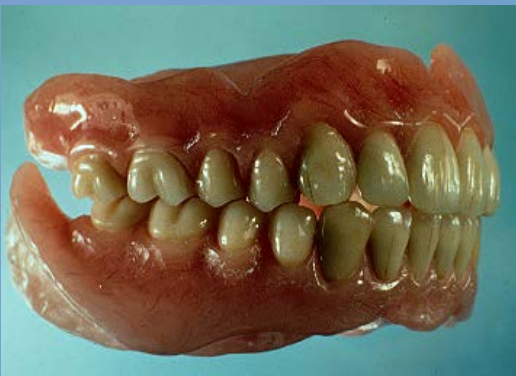
UiT

NORGES  
ARKTISKE  
UNIVERSITET

# Pasienten med avtakbar protese i tannløs kjeve

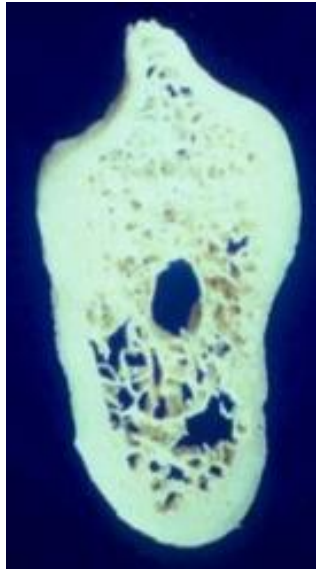
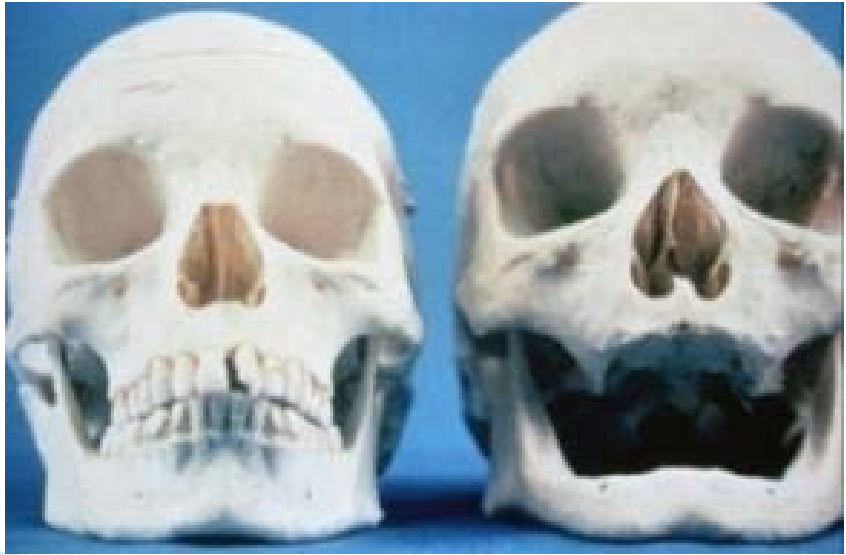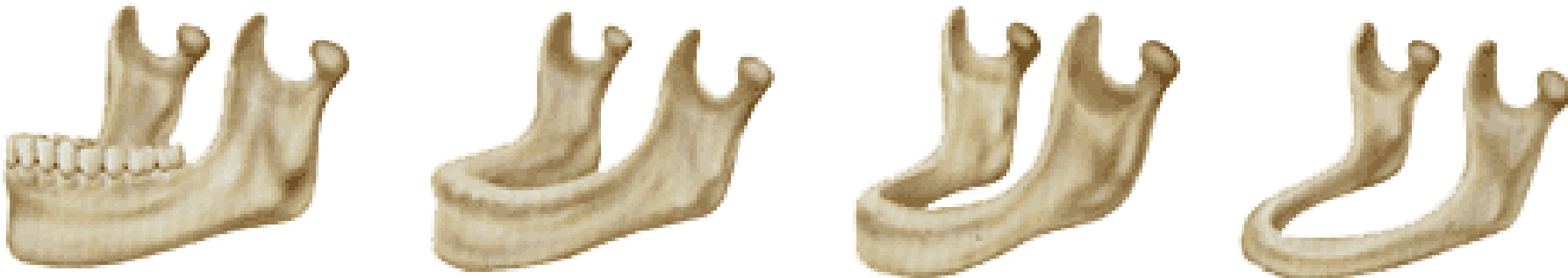---



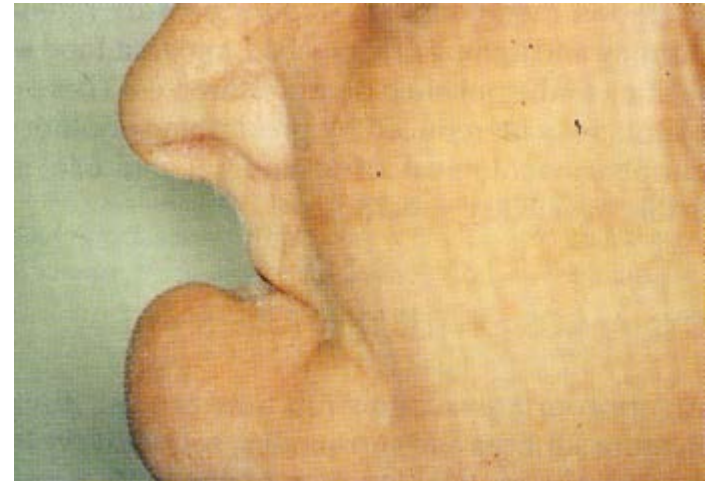
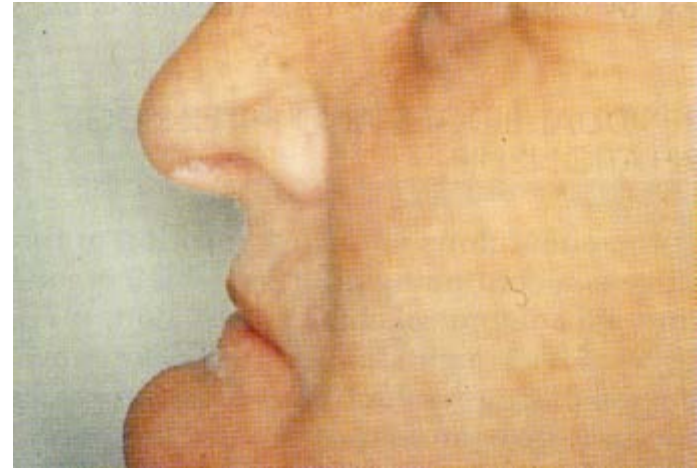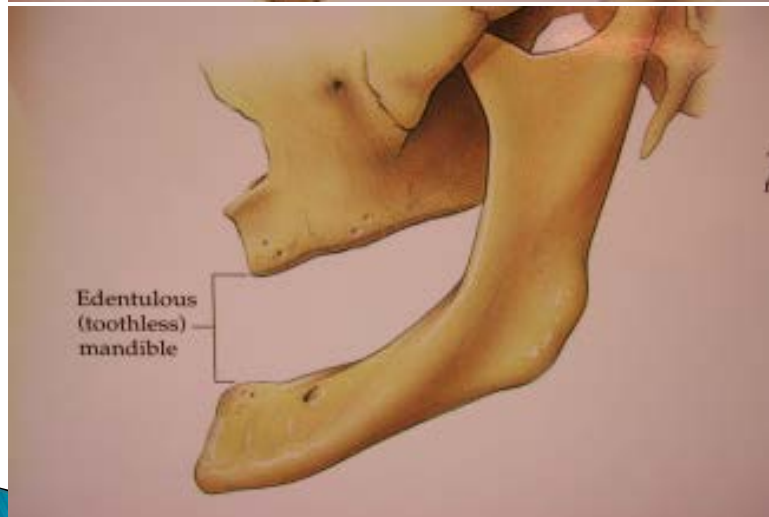
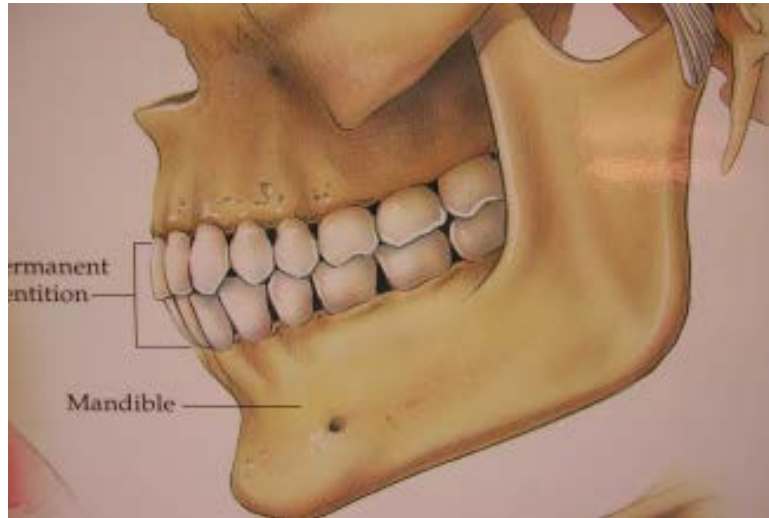
*Asbjørn Jokstad  
Institutt for klinisk odontologi  
UiT Norges arktiske universitet*



# *Ekstraksjon → v.tap av alveolarkam*



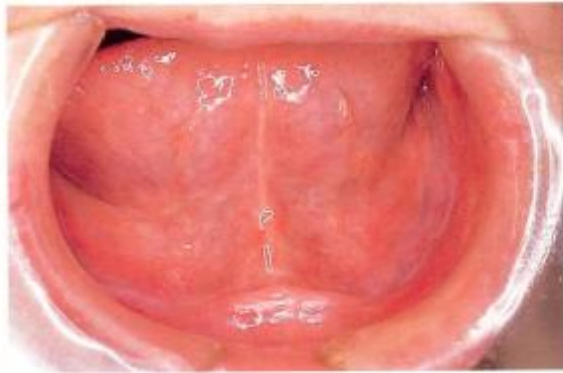# *Ekstraksjon → h.tap av alveolarkam*



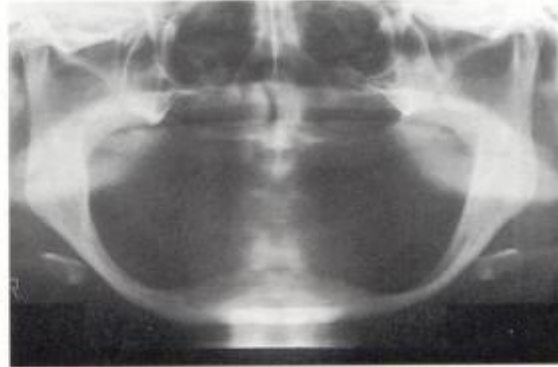
Fra: Budtz-Jørgensen 1996

Fra: Öwall, Käyser & Carlsson. 1996

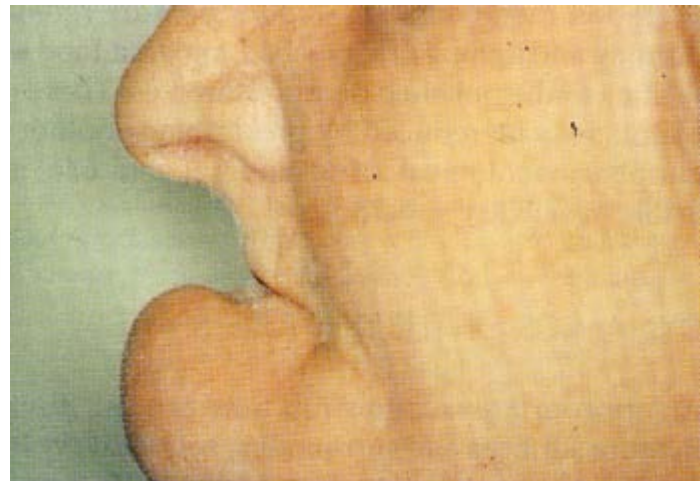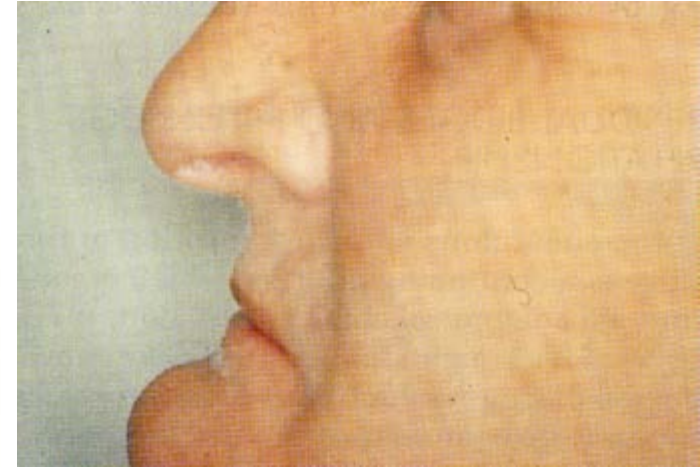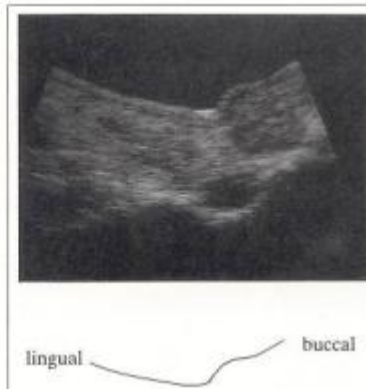
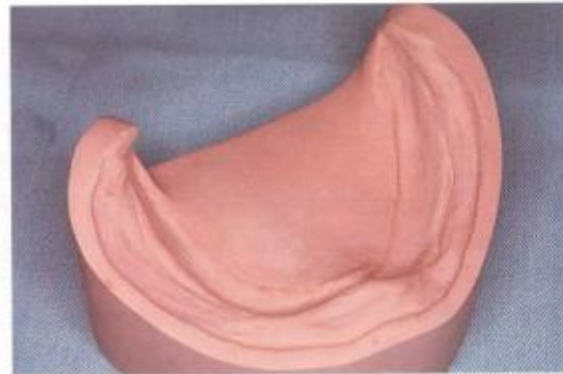# *Ekstraksjon → tap av alveolarkam*

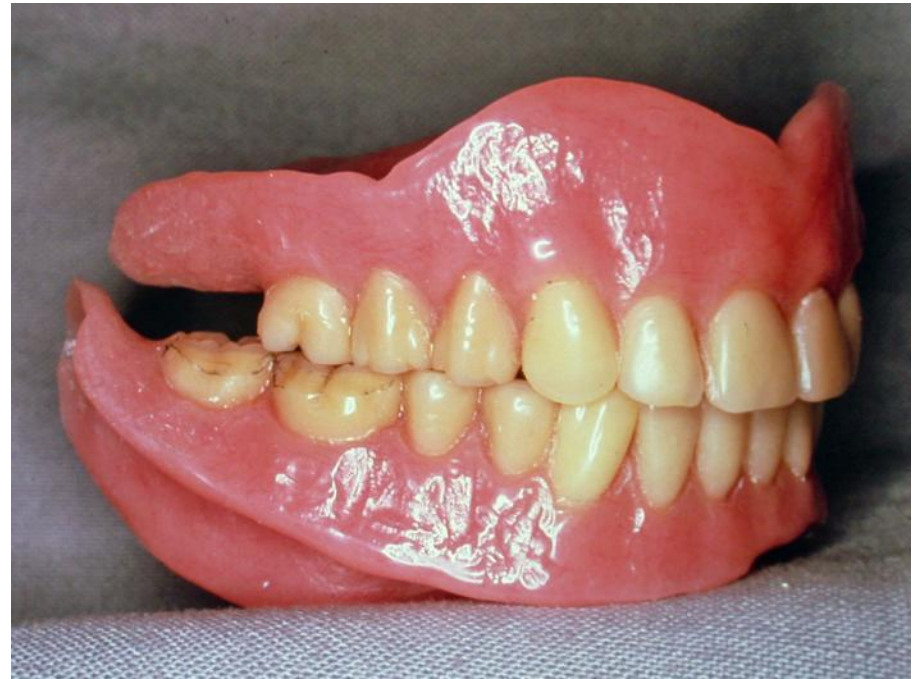
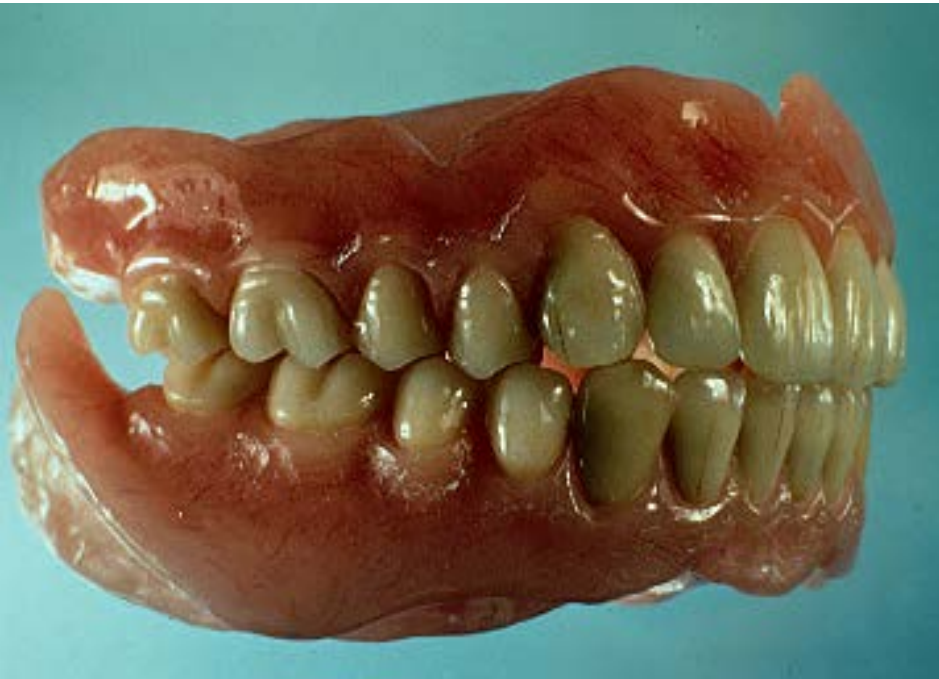
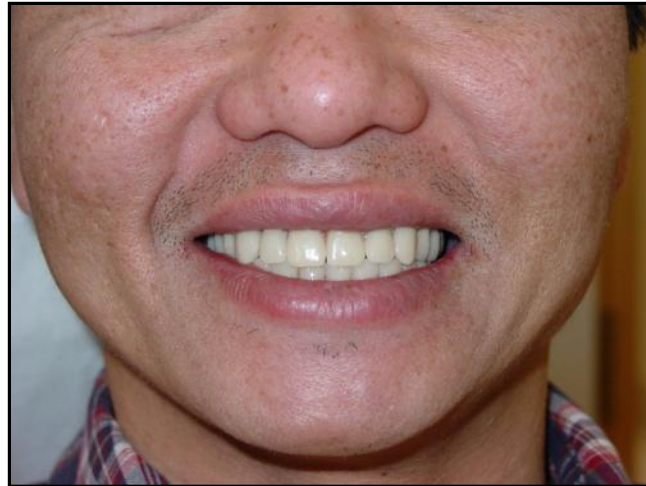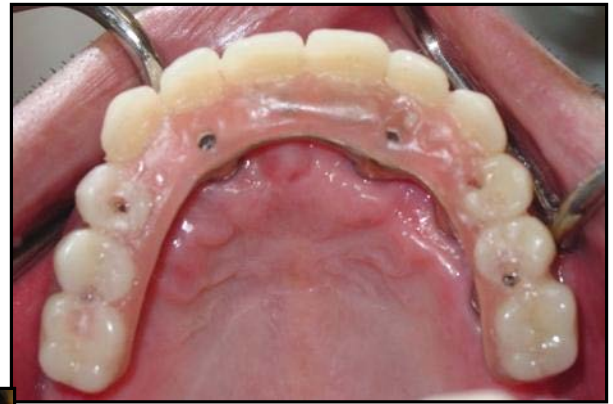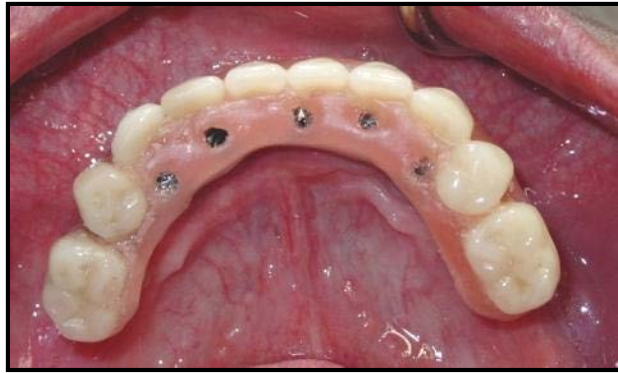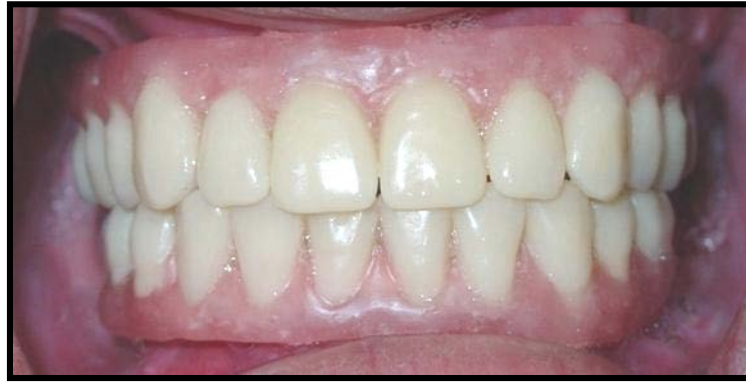a



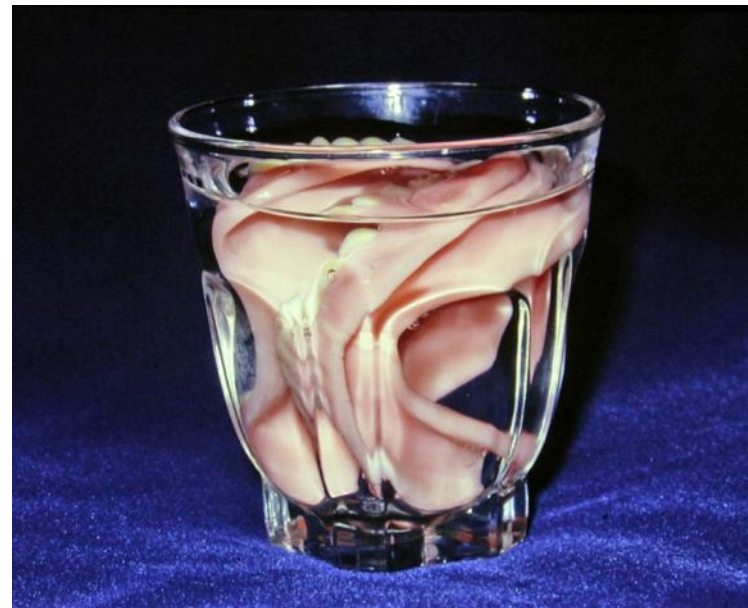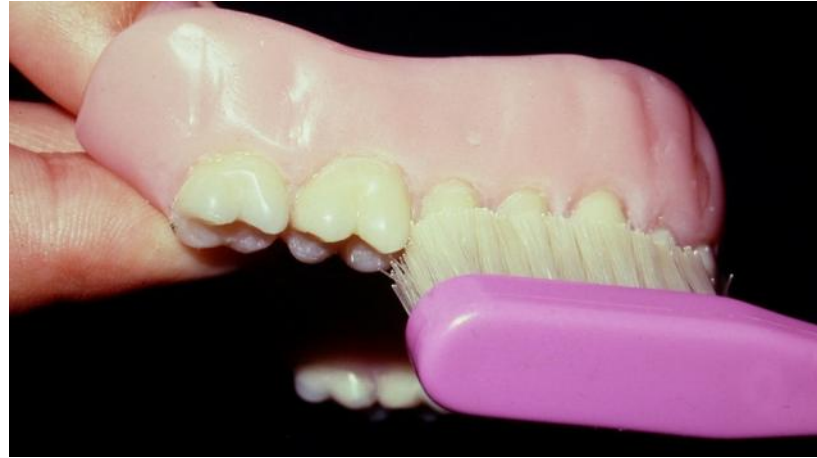b





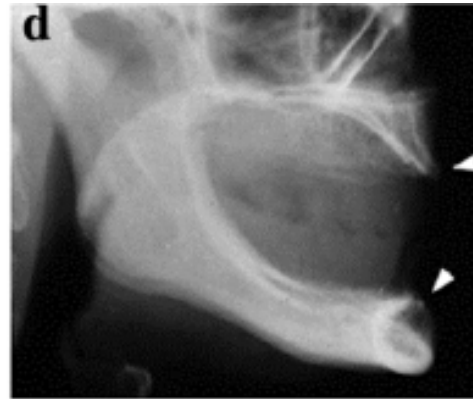
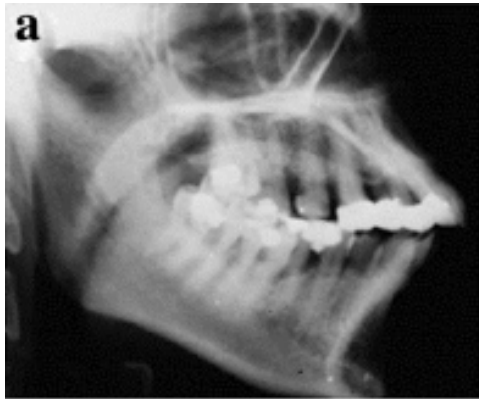

# Pasientinstruksjoner



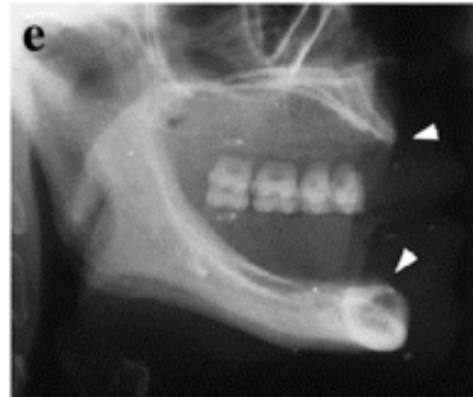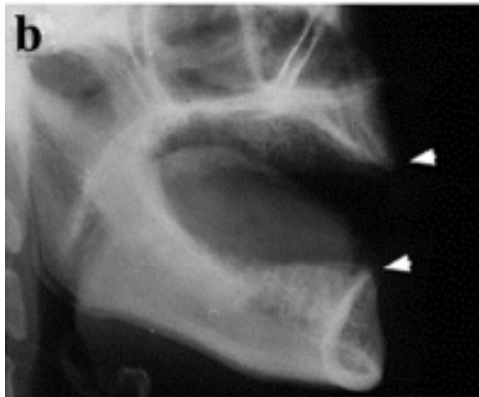
# *Ekstraksjon → tap av alveolarkam*

Pre-ekstraksjon  
(a)



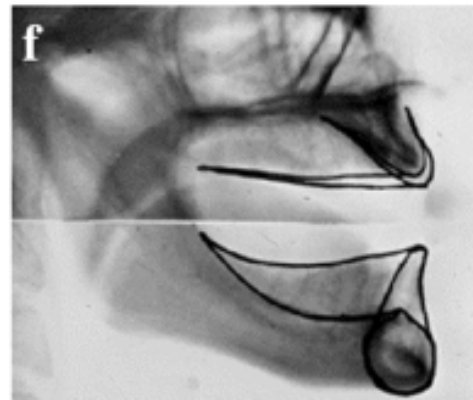
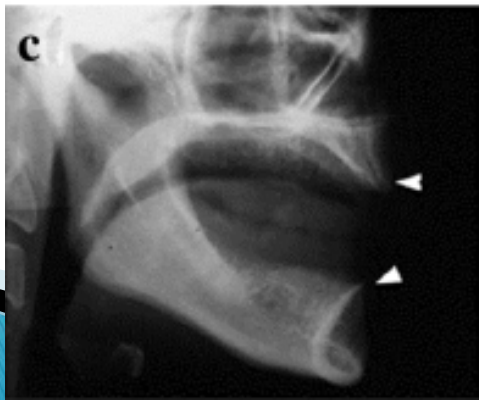
17 years  
postekstraksjon

3 months post-  
ekstraksjon



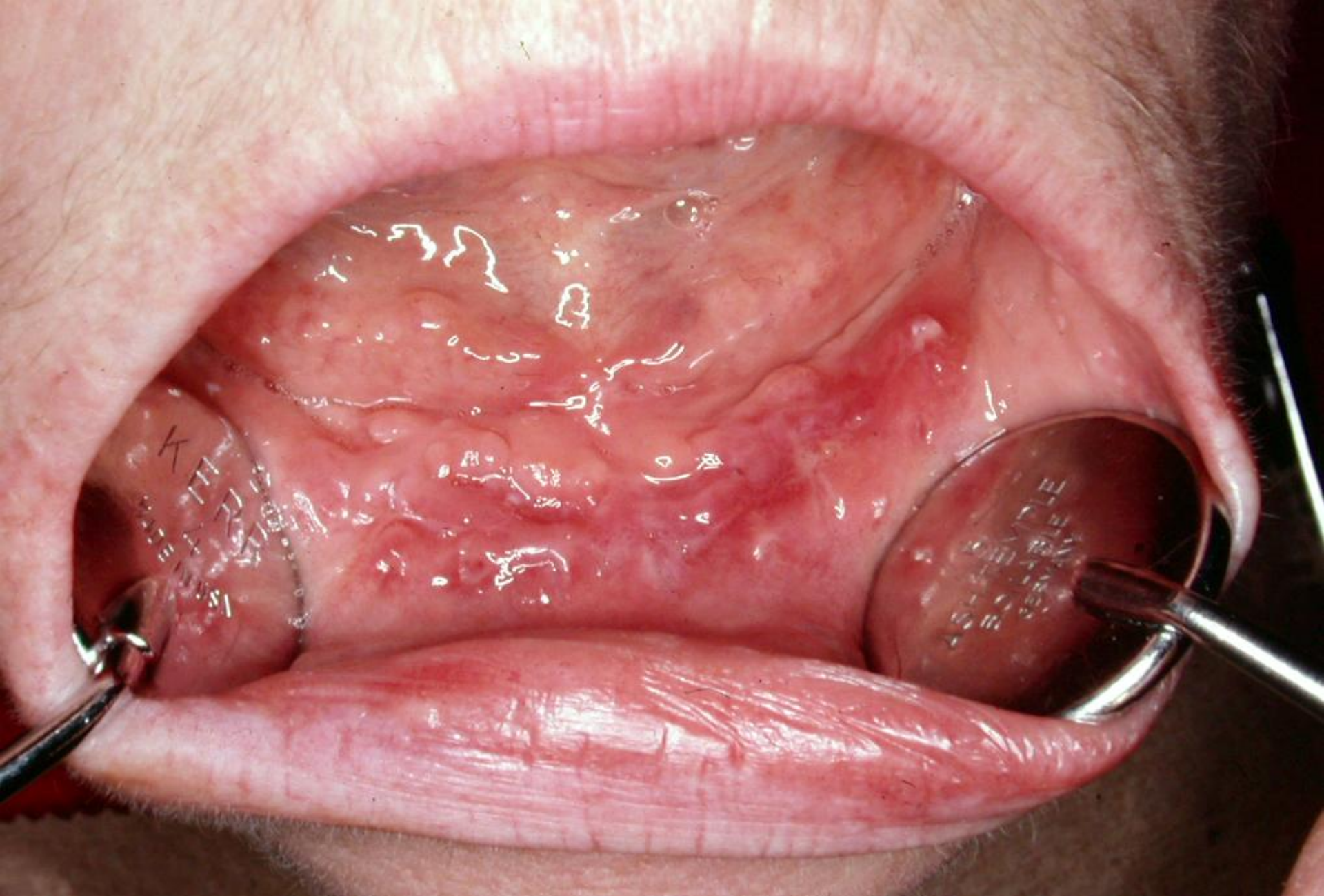25 year  
postekstraksjon

7 months post-  
ekstraksjon

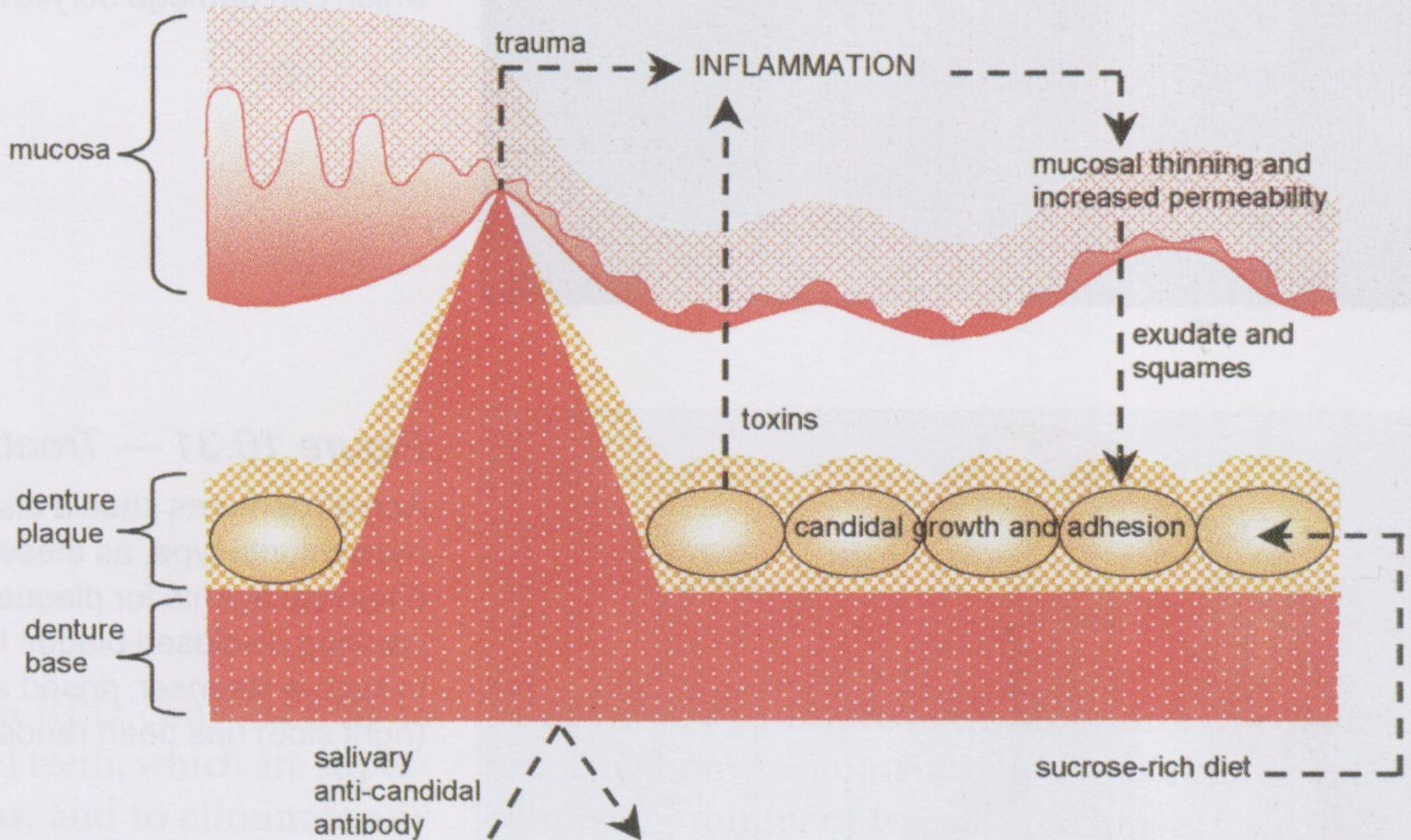


From Nishimura et al.  
Gerodontology 2004



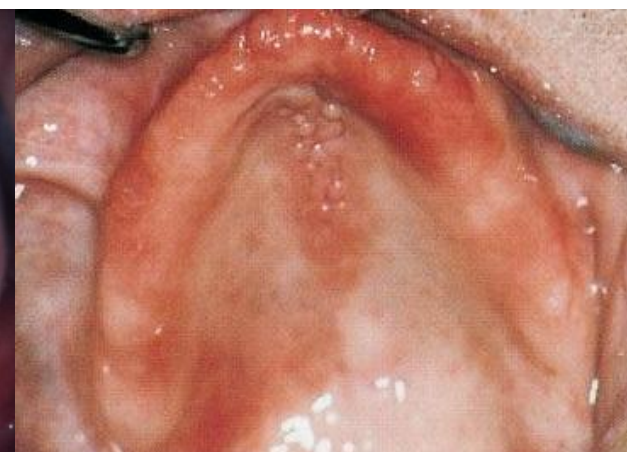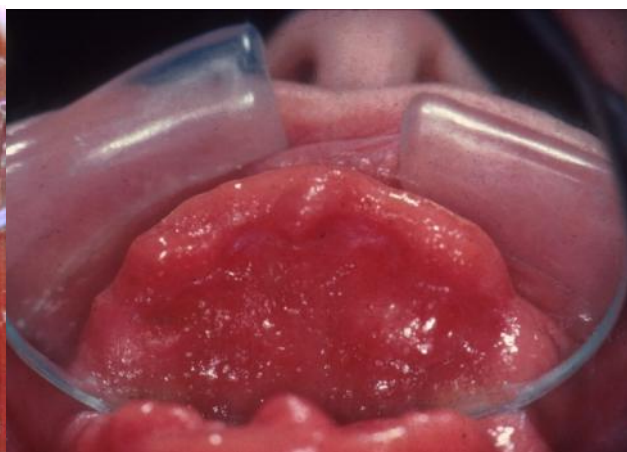
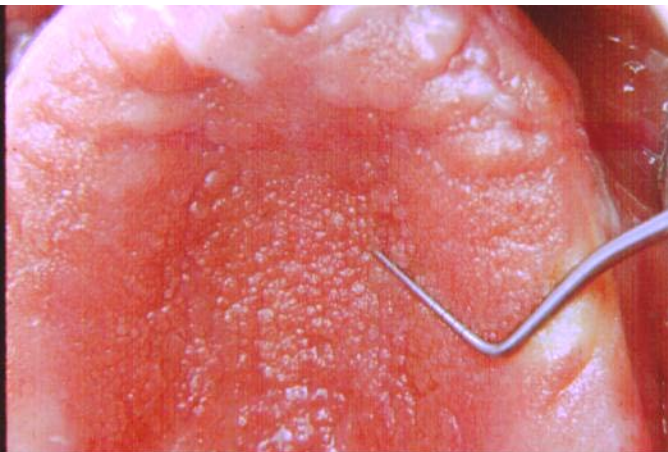
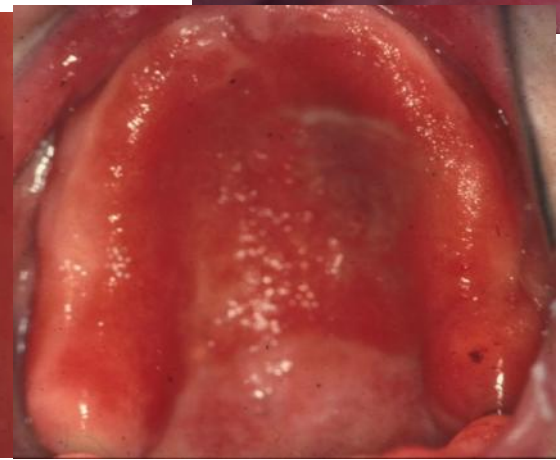
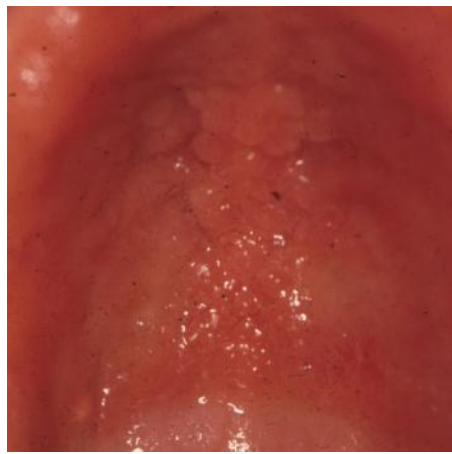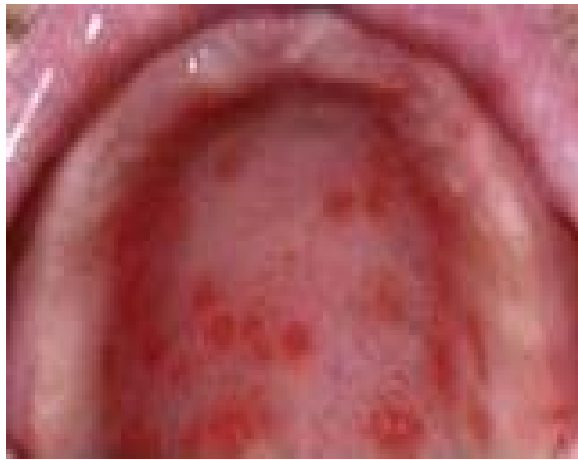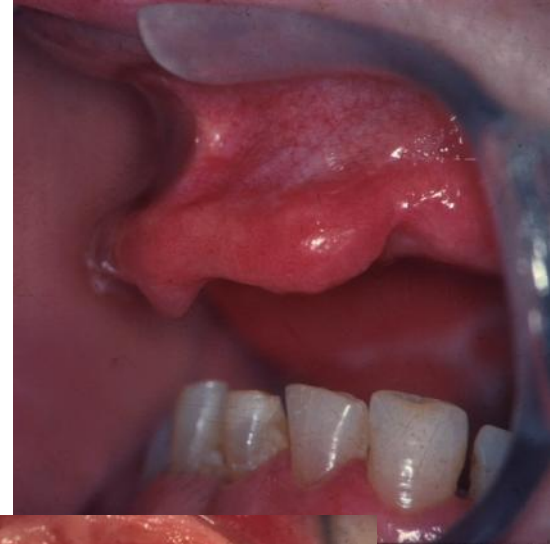


# Proteserelatert Candidose - etiologi



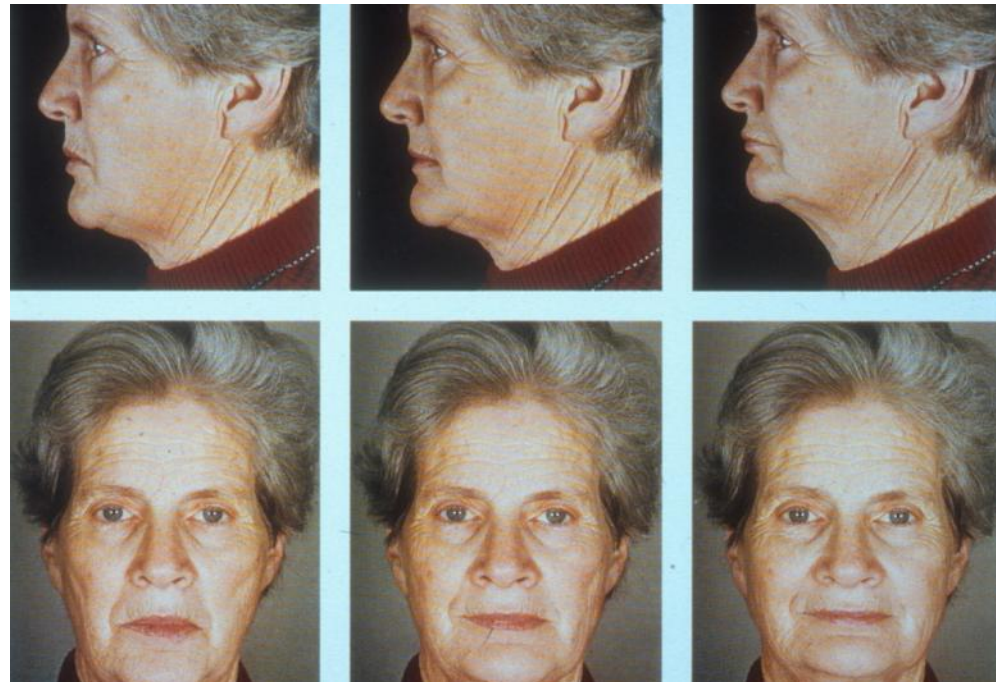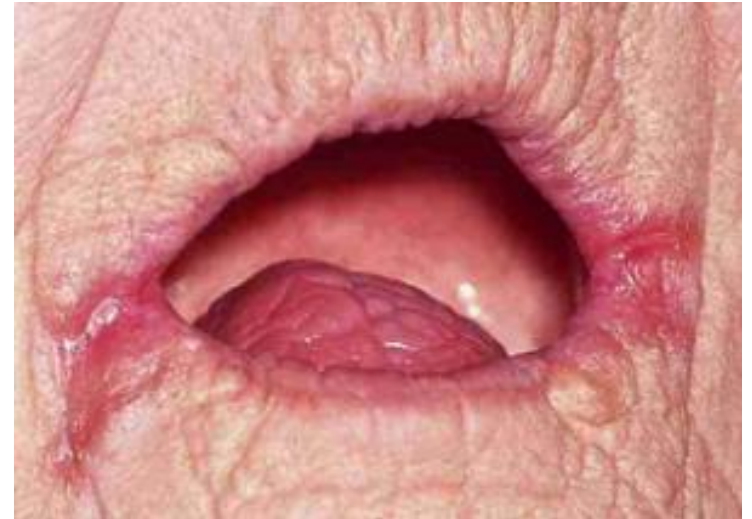# Hjelp

- ▶ Stomatitt



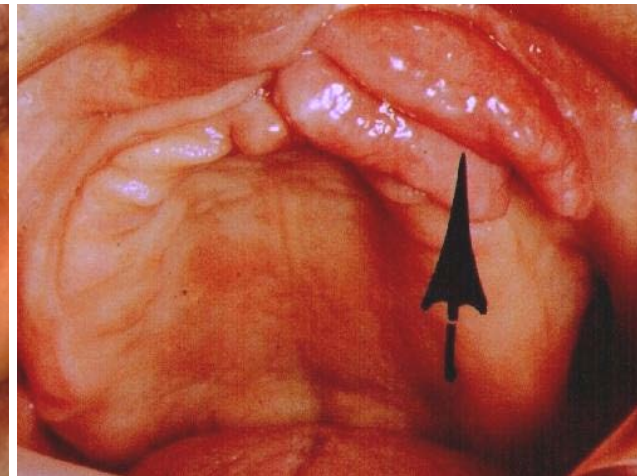
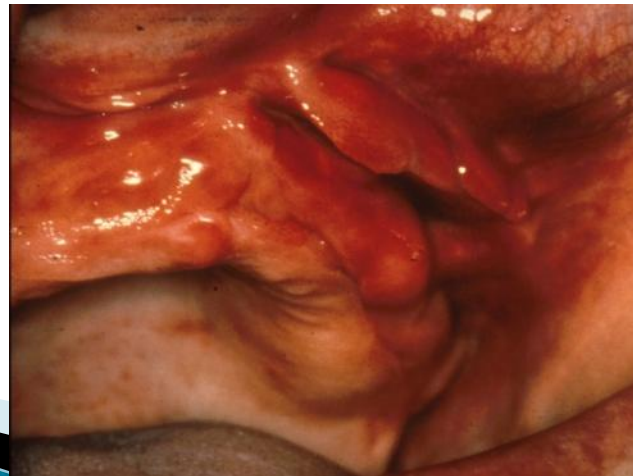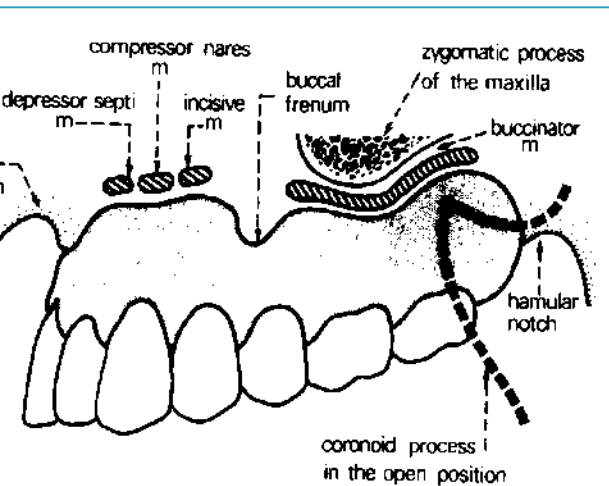
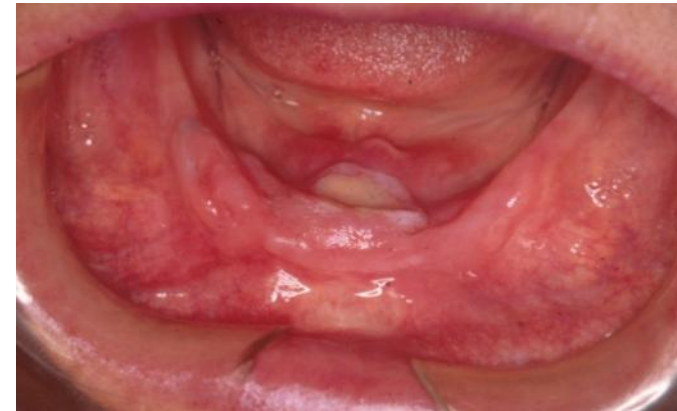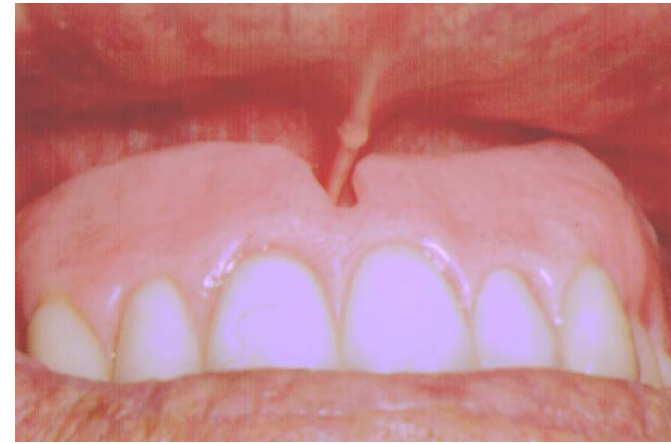# Hjelp

- ▶ Stomatitt
- ▶ Cheilitt – Manglende vertikal dimensjon (VDO)

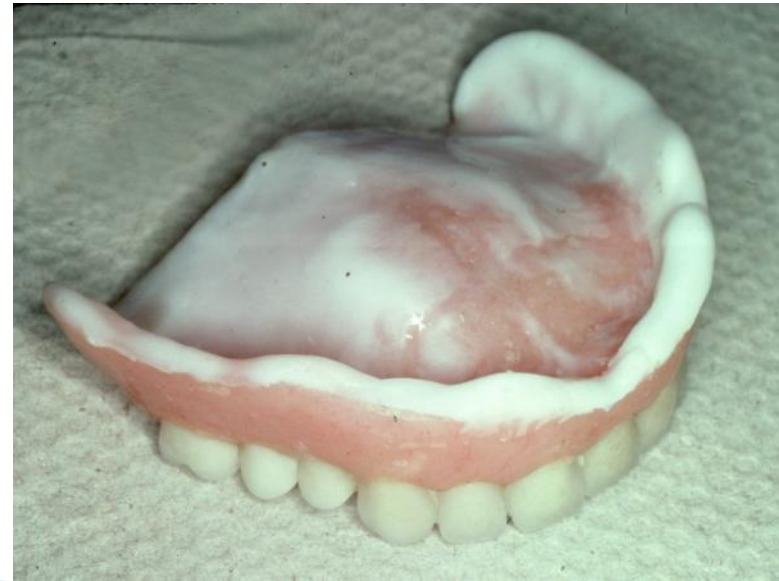
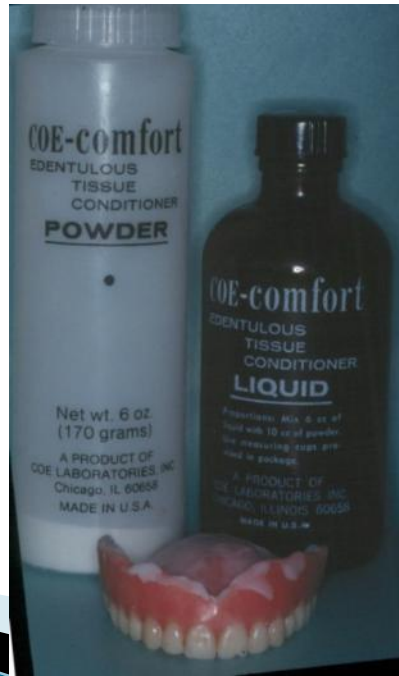
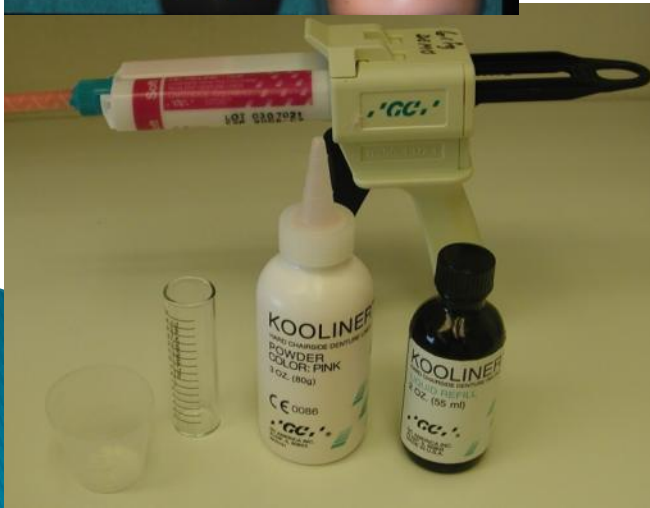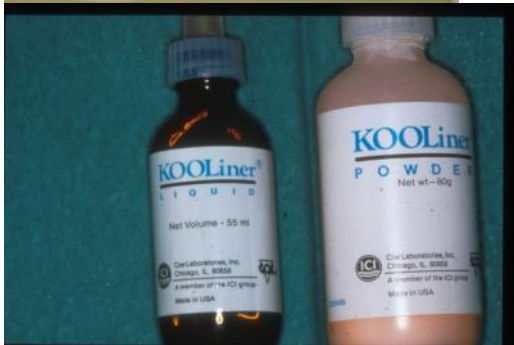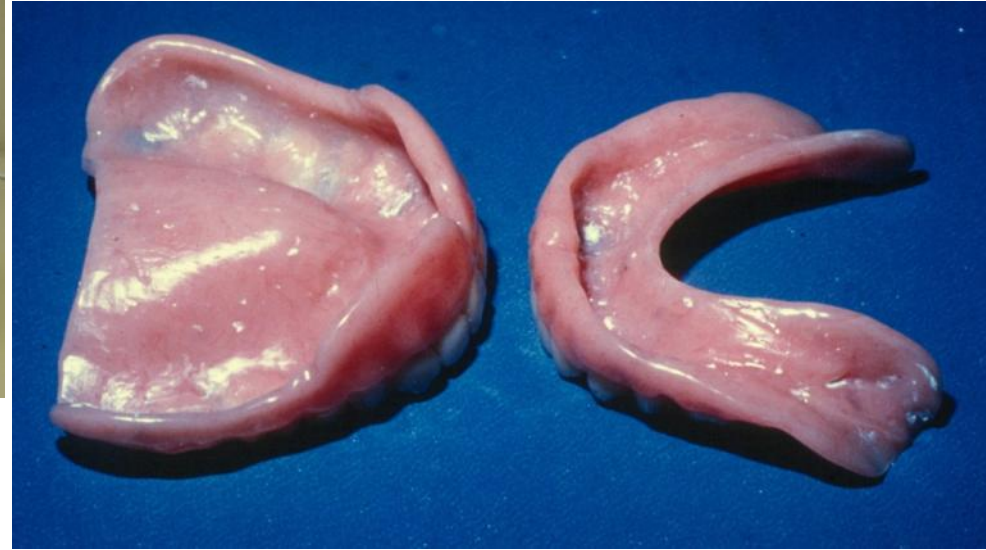# Hjelp

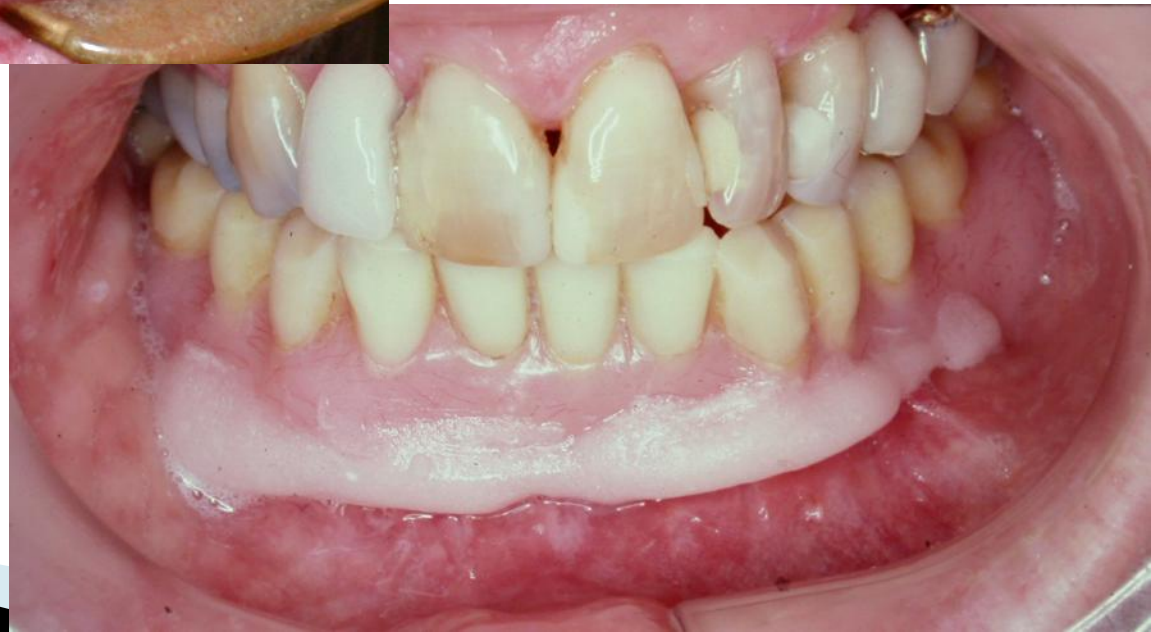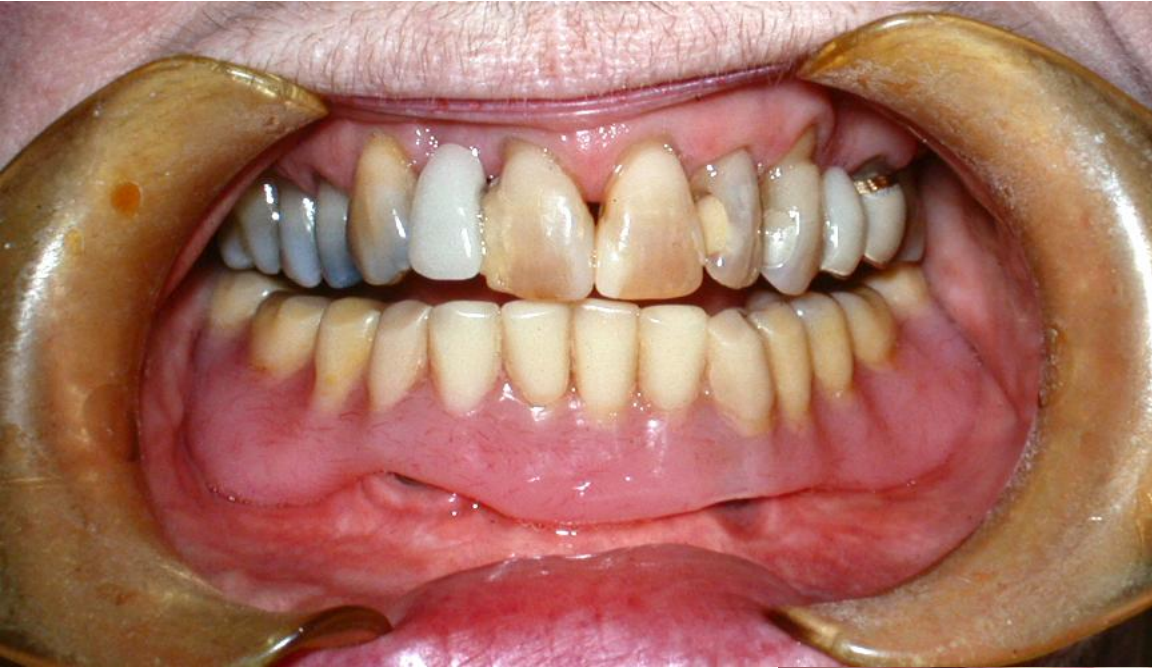- ▶ Stomatitt
- ▶ Cheilitt – VDO
- ▶ Overekstensjon



# Reliner-produkter



# Liner + tilheling 3 mnd



# Flabby ridge

- ▶ Bevegelig og ekstremt resilient alveolærkam
- ▶ Erstatning av ben med fibrøst bindevev
- ▶ Særlig prevalent i overkjevens front

